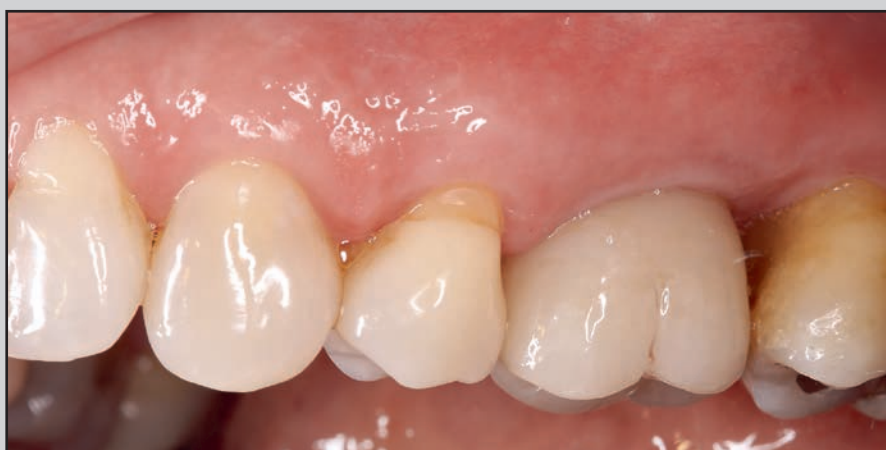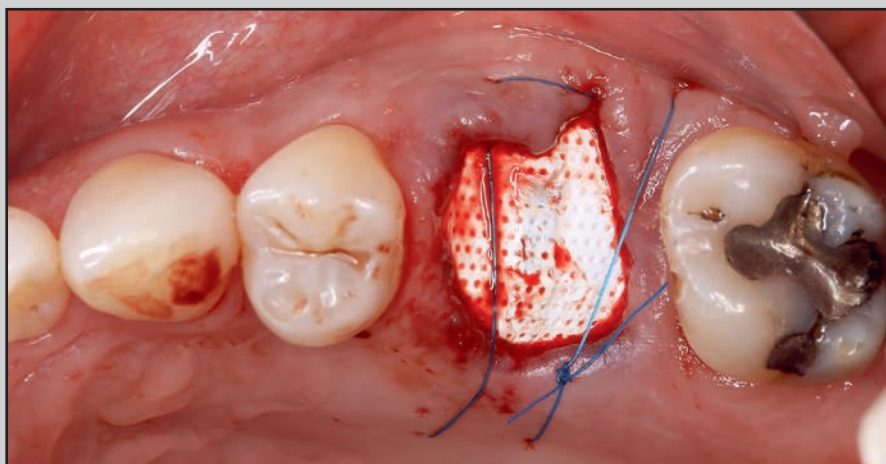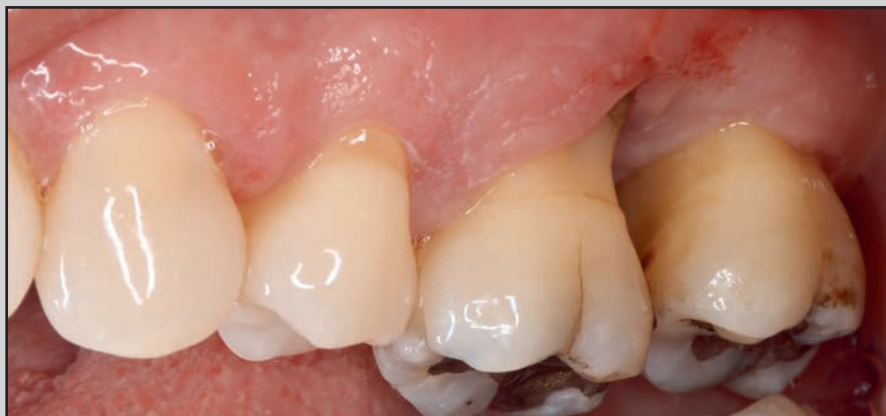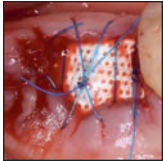


# Alveolar Ridge Preservation and Restoration with Titanium-Reinforced d-PTFE Membranes and Bone Substitutes of Severely Resorbed Sockets: A Pilot Case Series Study



Melle G. Vroom, DDS, MSc<sup>1</sup>  
Lodewijk J. M. M. Gründemann, DDS, MSc<sup>1</sup>  
Istvan Urban, PhD<sup>2</sup>

*This pilot case series study reports the dimensional alveolar bone changes after reconstruction of severely resorbed postextraction sockets treated with a mixture of particulate bone allograft and xenograft in combination with titanium-reinforced dense polytetrafluoroethylene (Ti-d-PTFE) membranes. Ten subjects who required premolar or molar extraction were included. Bone grafts were protected with Ti-d-PTFE membranes, utilizing an open-healing environment; membranes were removed 4 to 6 weeks after extraction, and implants were placed 6.7 months (mean) after extraction (T1). One patient required additional augmentation to correct an apical undercut of the alveolar process that was present preextraction. All implants integrated well and showed an implant stability quotient (ISQ) value between 71 and 83. The mean horizontal ridge width reduction from baseline (extraction) to T1 was 0.8 mm. Throughout the study, the mean vertical bone gain increase ranged from 0.2 mm to 2.8 mm (mean keratinized tissue width increase: 5.8 mm). The ridge preservation/restoration technique showed good preservation and restoration of severely resorbed sockets as well as improved amounts of keratinized tissue. If implant therapy is required after tooth extraction and severely resorbed sockets are present, the use of a Ti-d-PTFE membrane is a realistic option. Int J Periodontics Restorative Dent 2023;43:291–299. doi: 10.11607/prd.6336*

After tooth extraction, resorption of the extraction socket is a natural occurring phenomenon. Van der Weijden et al reported a mean horizontal reduction of 3.87 mm and a midbuccal height reduction of 1.67 mm after tooth extraction.<sup>1</sup> Ten Heggeler et al reported a horizontal reduction of 2.6 to 4.6 mm and a height reduction of 0.4 to 3.9 mm for nonmolar extraction sockets.<sup>2</sup> Various ridge preservation techniques have been developed to counteract resorption. Ten Heggeler et al also concluded that although various socket preservation techniques may reduce resorption, losses in width and height may be expected (up to 3.48 mm and 2.64 mm, respectively), suggesting that implant placement may require additional augmentation due to the treatments not completely preventing bone resorption. Ridge preservation studies on severely resorbed extraction sockets are rare.<sup>3–8</sup> In 2001, Bartee introduced the use of dense polytetrafluoroethylene (d-PTFE) membranes in ridge preservation,<sup>9</sup> and positive results have been reported with some resorption.<sup>10–12</sup> To the best of the present authors' knowledge, no case series study has been reported using titanium-reinforced d-PTFE (Ti-d-PTFE) membranes in ridge preservation procedures. Schenk et al described the healing under PTFE membranes in guided bone regeneration

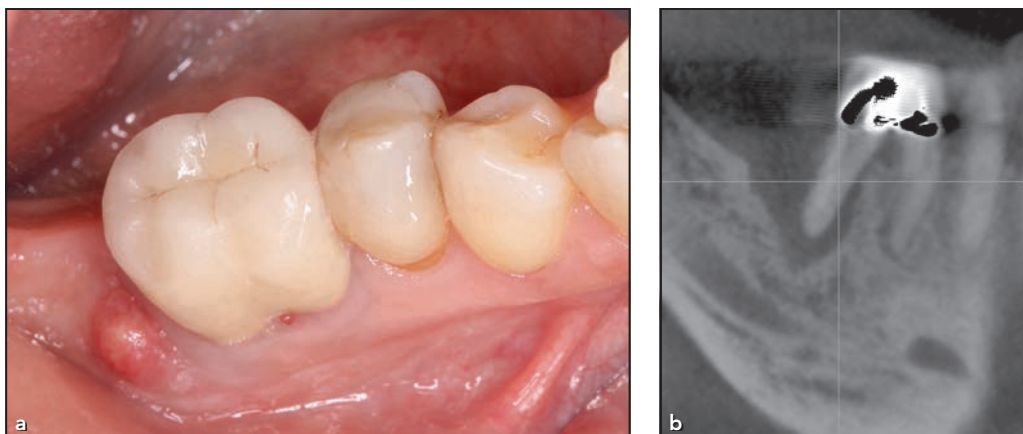
<sup>1</sup>Private Practice, Leeuwarden/Goutum, The Netherlands.

<sup>2</sup>Private Practice Budapest, Hungary.

Correspondence to: Dr Melle G. Vroom, Practice for Periodontology Friesland, Bredek 1-B, 9084 AG Goutum, The Netherlands. Email: PPF@parofries.nl

Submitted April 20, 2022; accepted October 6, 2022.

©2023 by Quintessence Publishing Co Inc.



**Fig 1** Example case 1. (a) Clinical view before extraction. A fistula is present on the distal site. (b) A CBCT scan shows advanced bone loss.

procedures,<sup>13</sup> reporting that the reinforced version reliably preserves the original form better than the nonreinforced PTFE membranes. Therefore, the aim of the present study was to investigate the dimensional postextraction alveolar bone changes of severely resorbed sockets treated with bone substitutes in combination with Ti-d-PTFE membranes.

## Materials and Methods

In total, 10 patients (7 women and 3 men) with a mean age of 59 years (range: 50 to 69 years) who required extraction of maxillary or mandibular premolars or molars were enrolled in this case study. The inclusion criteria were as follows: (1) age > 18 years; (2) premolars and molars with advanced periodontal bone loss with or without periapical pathology; (3) > 50% of the buccal and/or palatal/lingual alveolus wall missing; (4) smoking < 10 cigarettes per day; (5) presence of a papilla that covered a membrane edge; (6) at least one neighboring tooth; (7) received periodontal treatment; and (8) understood and signed

the consent form. The presence of a fistula was accepted.

The exclusion criteria were as follows: (1) uncontrolled diabetes; (2) immunosuppression; (3) organ failure; (4) severe metabolic bone disease or disorders; (5) history of head or neck radiotherapy; (6) chemotherapy within the past 12 months; and (7) pregnancy.

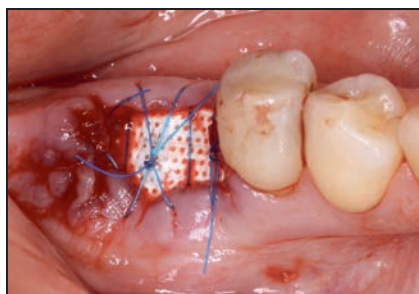
Informed consent was obtained from patients based on the Declaration of Helsinki as revised in 2000.

### Clinical Procedure

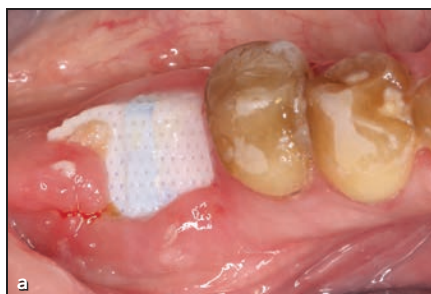A CBCT scan was performed with a field of view that covered the extraction site and the neighboring teeth (Pax Duo/One [Vatech] for nine patients; Kodak 9000 3D [Kodak] for one patient). An alginate impression was also made. Clinical slides were taken, and the probing pocket depth, recession, keratinized mucosa width, and clinical attachment level (CAL) of the tooth to be extracted and neighboring teeth were measured using a periodontal probe (Williams Probe, Hu-Friedy)

before surgery (baseline; T0) (Fig 1). A stone cast model was made from the impression.

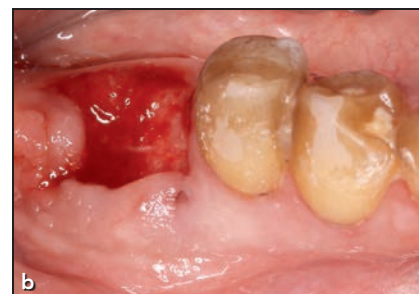All clinical procedures were performed by one operator (M.V.). Patients rinsed with 0.2% chlorhexidine for 1 minute and received painkillers (1 g paracetamol). Local anesthesia (10 µg adrenaline, 1:100,000 articaine, Septanest) was administered. A piezoelectric device was used to achieve atraumatic extractions; if needed, molars were hemisected. If proper debridement was not possible, a local full-thickness flap was elevated to allow better access for debridement. After debridement and irrigation with sterile saline, the tissues around the extracted tooth were separated from the underlying bone with a periodontal elevator and a tunneling instrument to create an envelope flap. The postextraction alveolar ridge width in the buccolingual/palatal direction was measured at the crest using a caliper (40-mm Curved Castroviejo Bone Caliper, Hu-Friedy). The site with the most advanced vertical bone loss was registered and measured from the highest neighboring alveolar crest



**Fig 2** Clinical view of the Ti-d-PTFE membrane in position and bent in a U-shape.



**Fig 3** (a) The Ti-d-PTFE membrane at 5 weeks postoperative. The discoloration caused by chlorhexidine rinsing is visible. (b) Clinical view immediately after membrane removal.



with a periodontal probe. Blood was collected from the surgical site with a syringe and mixed with a combination of a particulate allograft (mineralized cortical and cancellous mixture; MinerOss, BioHorizons) with a xenograft deproteinized bovine bone mineral (Bio-Oss, Geistlich) in a 60:40 ratio. Between 4 and 8 mg of tetracycline powder was applied to the bone mixture as an anti-inflammatory agent. A nonresorbable Ti-d-PTFE (Cytoplast ANL30, Osteogenics Biomedical) was trimmed to a shape that covered the complete alveolar bony housing. If insufficient bleeding was present in the alveolus, bone perforations were generated to provoke bleeding. The mixed bone graft was placed in the alveolus and shaped to mimic a nonresorbed alveolar process. The Ti-d-PTFE membrane was bent in a U shape according to the width of the desired alveolar process and placed, with the dimpled surface up, beneath the tissues of the extraction site to ensure compartmentalization of the underlying alveolus and applied bone graft. Care was taken that the membrane did not touch a neighboring tooth. The marginal mucosa and, if applicable, the elevated local flap were stabilized with an ex-

ternal cross-mattress or single sutures (Ethilon II 5-0, Ethicon). Suture knots were applied with light force to keep the marginal gingiva position at the original preextraction position. No primary closure was intended (Fig 2).

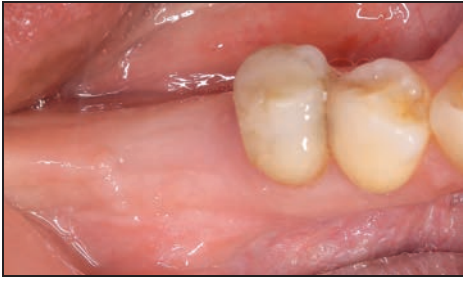
Postsurgical care comprised rinsing with 0.2% chlorhexidine twice a day for the first 2 weeks and once a day for the following 2 to 3 weeks. On indication, antibiotics were prescribed (500 mg amoxicillin three times a day for 3 days)<sup>14</sup> depending on the amount of infection present before extraction. If needed, patients were allowed to use painkillers, including paracetamol (maximum: 3 g per day). The sutures and membrane were removed together, without anesthesia, after 4 to 6 weeks, and patients were instructed to rinse with chlorhexidine the following day up to 4 days later (Fig 3). Although the chlorhexidine rinsing has shown in vitro toxic effects on fibroblasts,<sup>15</sup> the present authors advised rinsing to support the plaque control at the surgical site and neighboring teeth.

After 5 to 12 months (mean: 6.7 months), a new alginate impression (second stone model) and clinical slides were made immediately before implant surgery (T1) (Fig 4). On

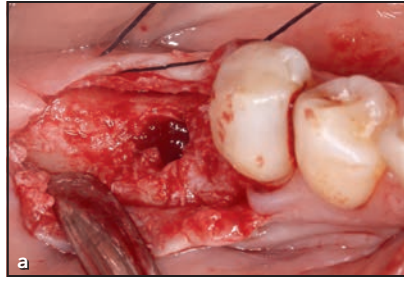
the baseline stone model, a putty mold was made with notches in the direction of the sulcular region of the extracted tooth to record the T1 tissue thickness measurements. These tissue thickness measurements were performed at eight sites (mesiovestibular, mesio-occlusal, mesiolingual/-palatal; midvestibular, midlingual/-palatal; distovestibular, disto-occlusal, and distolingual/-palatal) in the healed extraction site with a periodontal probe (Williams Probe).

One hour before implant placement, patients were given 2 g amoxicillin. A full-thickness flap was elevated, and an implant was placed (Meisinger implants, Oktagon) (Fig 5). Primary stability was measured with the needed insertion torque. The alveolar width was measured with a caliper at the crest, and tissues were then sutured. After 2 to 4 months of healing, an implant stability quotient (ISQ; Osstell scale) was measured to test the secondary stability, and a radiograph and clinical slide were acquired (Fig 6). The implants were successfully restored by referring dentists (Fig 7).

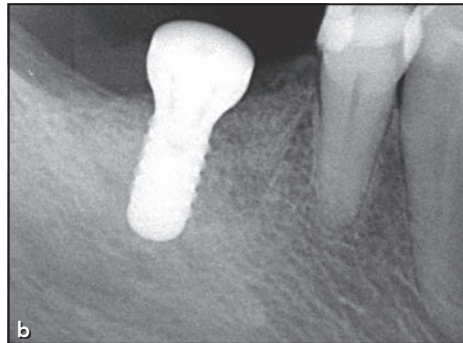
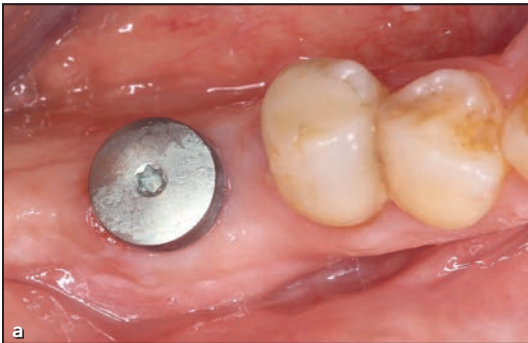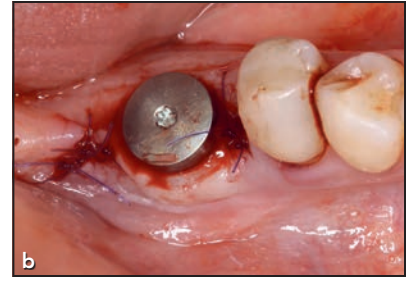
Based on the CBCT scan at T0, the bony defect around the tooth to be extracted was assessed for



**Fig 4** Clinical view 5 months after extraction with a broad zone of keratinized tissue.



**Fig 5** Clinical views (a) immediately after osteotomy preparation and (b) implant placement.



**Fig 6** (a) Clinical and (b) radiographic views 2 months after implant placement.

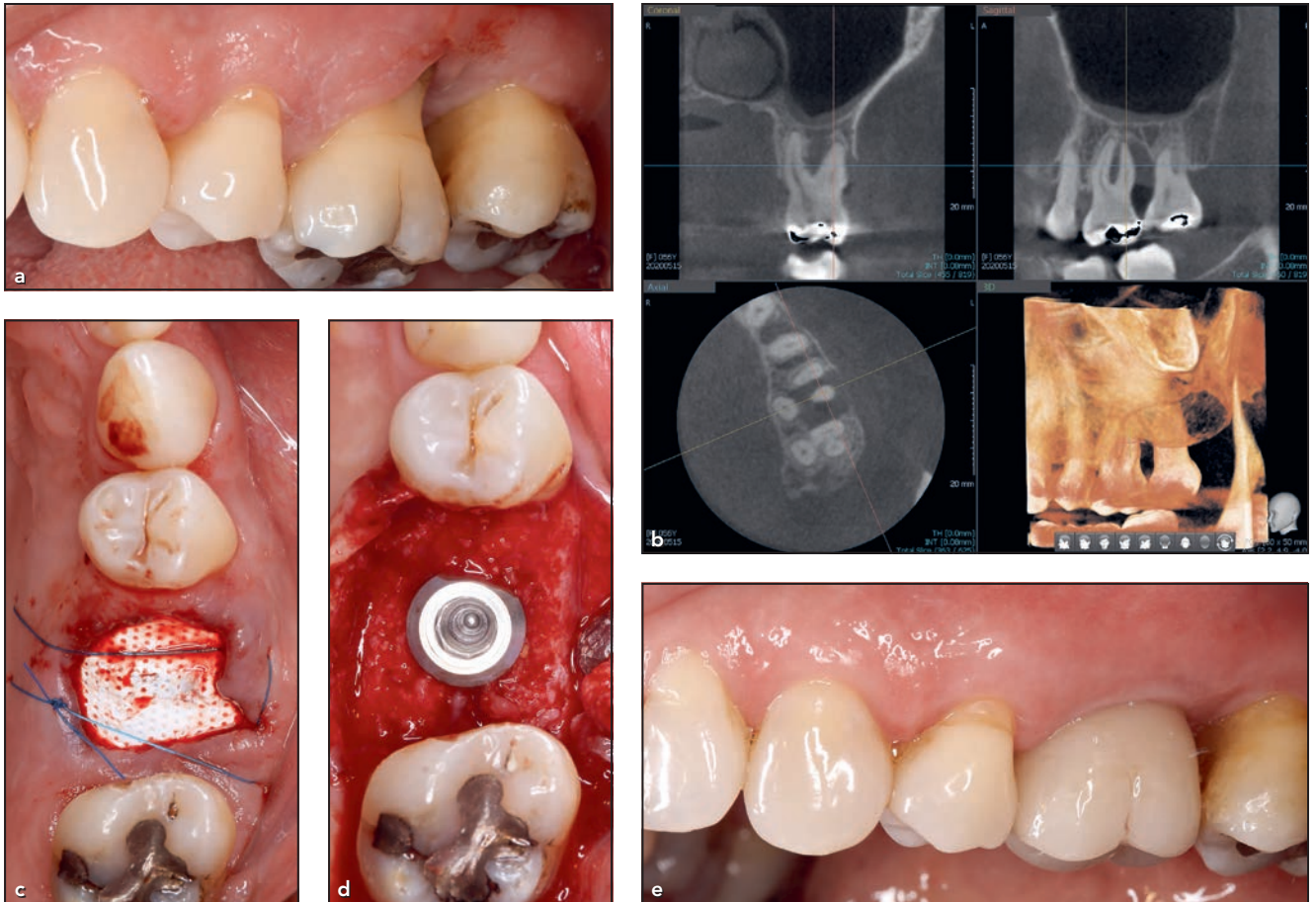all patients. On the second stone model, the tissue thickness measurement sites were marked with a pencil using the putty mold. On these sites, gutta-percha points (3 to 5 mm long) were positioned with wax to allow identification of each point on a CBCT scan. A CBCT scan (Green 16, Vatech) of the model was acquired using the "model-mode" to store the plaster model as a digital model. The stone cast model was then superimposed (EZ 3D-i software, Vatech) on the baseline CBCT using the neighboring teeth as reference points. At each of the eight measurement points, a vertical measurement was made from the border of the stonecast model to the first bone level at the baseline CBCT and marked with a gutta-percha point (Fig 8). At each site, the T1 vertical

soft tissue thickness was subtracted from the T0 vertical measurement on the CBCT scan, with the result indicating the vertical bone loss or gain from T0 to T1. The reproducibility of the CBCT scan measurements was tested by repeating 10% of these measurements, which resulted in a mean difference of  $-0.2 \pm 0.8$  mm.

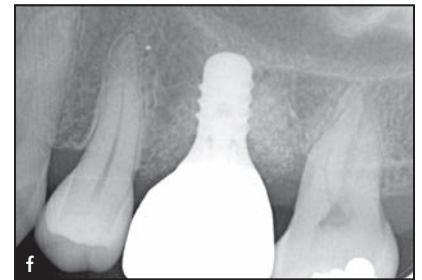## Results

The extracted teeth comprised three maxillary molars, two maxillary premolars, and five mandibular molars. Of the 10 patients, 6 were prescribed antibiotics (500 mg amoxicillin three times a day for 3 days). Two patients smoked < 10 cigarettes per day, and a fistula was present in 2 patients at the time of extraction but not when

the membrane was removed. At membrane removal, a part of the membrane edge was visible in 4 patients, newly formed tissue was visible for all patients, and some bleeding occurred but stopped quickly. In 4 patients, a few bone graft particles were visible in the upper part of the newly formed tissue, which were removed with gentle sweeping of a periodontal probe. In 1 patient, the upper surface consisted of loose particles, which were removed until newly formed tissue with integrated particles became visible. All sites healed well after extraction. At a mean of 6.7 months postextraction (range: 5 to 12 months), an implant was placed with an insertion torque of 25 to 35 Ncm in 9 patients. In 1 patient, an additional bone augmentation was required to correct an apical



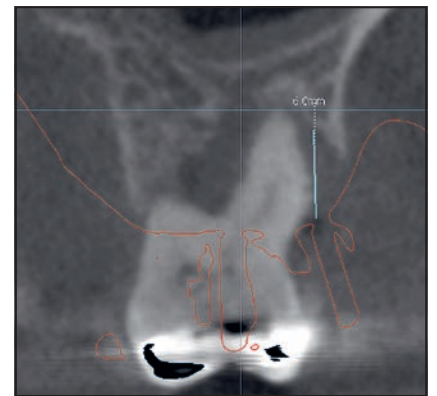
**Fig 7** Example case 2. (a) Clinical view before extraction. (b) CBCT scans show advanced bone loss around a first molar. (c) Clinical view of the Ti-d-PTFE membrane in position after tooth extraction. (d) Occlusal view after implant placement. (e) Clinical and (f) radiographic views 6 months after crown placement.



**Fig 8** The stone cast model was superimposed on a CBCT scan. The red projection illustrates one of the gutta-percha reference points.

undercut of the alveolar process, which was present preextraction. One patient postponed implant placement due to personal reasons, but this patient allowed clinical measurements to be performed at T1 without flap elevation. All implants integrated well and showed an ISQ value between 71 and 83.

The mean keratinized tissue width was  $6.0 \pm 1.0$  mm at T0 and



**Table 1 Location of the Most Advanced Vertical Bone Loss Around Extracted Teeth**

Patient no.	Affected socket walls		Vertical bone loss	Neighboring teeth, n	Largest CAL
	n	Location			
1	2	Mesial and palatal	8 mm	1	4 mm
2	2	Vestibular and distal	7.5 mm	2	7 mm
3	1	Vestibular	5 mm	1	3 mm
4	1	Vestibular	9 mm	2	5 mm
5	1	Vestibular	8 mm	2	4 mm
6	2	Vestibular and distal	8 mm	2	6 mm
7	1	Distal	9 mm	2	4 mm
8	1	Vestibular	9.5 mm	2	4 mm
9	2	Vestibular and distal	9 mm	1	3 mm
10	1	Lingual	6.5 mm	2	4 mm
Mean	–	–	8 mm	–	–

CAL = clinical attachment level.

Vertical bone loss was measured from the highest neighboring ridge. The largest CAL was measured at the interproximal site adjacent to the extraction site. Defects were evaluated at baseline (T0).

increased to  $11.8 \pm 2.3$  mm at T1. The mean tissue thickness at T1 was  $1.62 \pm 0.7$  mm. Details of the bony defects around each extracted tooth (the number of neighboring teeth, the highest CAL value at the neighboring teeth, etc) are listed in Table 1. In 4 patients, two affected ridge walls were present. The mean vertical bone loss at the bony defect was 8 mm. In 7 patients, a neighboring tooth was present on each side of the extraction site. The highest CAL value at the neighboring teeth varied between 3 and 7 mm, indicating that bony support for the membrane edge was reduced at these sites.

### Vertical and Horizontal Bone Change

The mean horizontal ridge width was  $10.5 \pm 2.84$  mm at T0 and  $9.7 \pm 2.05$  mm at T1, resulting in a mean

reduction of 0.8 mm (Table 2). Two of the 10 patients had a 4-mm width reduction, and the extracted tooth showed one root that was positioned partially outside the alveolar housing. In 1 patient, the alveolar width increased by 2 mm because the partially blown-out vestibular and distal ridge wall was restored at T1. The remaining patients showed a stable ridge width over time. The vertical bone changes between T0 and T1 for each patient are presented in Table 3. A mean vertical bone gain of 0.2 to 2.8 mm was seen. Regarding the sites, the highest vertical bone gain corresponded with the extraction sites for a majority of patients, with the most prominent bony defects at the time of extraction (Table 1).

### Discussion

This pilot case series study reports the postextraction dimensional al-

veolar bone changes of severely resorbed sockets treated with a mixture of particulate bone allograft and xenograft substitutes in combination with Ti-d-PTFE membranes. Only premolars and molars were included, as a larger amount of reduction occurs in the molar region following tooth extraction.<sup>16,17</sup> The treatment resulted in a mean vertical bone gain at all sites and a limited horizontal bone resorption (mean: 0.8 mm), contributing to a sufficient thickness of the peri-implant bone wall.<sup>18</sup> To investigate the potential of the present technique, only teeth with > 50% of the buccal and/or palatal/lingual alveolus wall missing at the time of extraction were included. Various ridge preservation studies have excluded such sites. The requirement for an additional augmentation indicates the efficacy of the ridge preservation/restoration technique. Antonious et al used nonreinforced

**Table 2 Alveolar Horizontal Ridge Widths at T0 and T1**

Patient no.	T0	T1	Difference	Remarks
1	12 mm	8 mm	-4 mm	Rotated molar. DB root partially outside of the alveolar process.
2	14 mm	13 mm	-1 mm	-
3	7 mm	6 mm	-1 mm	-
4	9 mm	9 mm	0 mm	-
5	17 mm	13 mm	-4 mm	Palatal and mesiobuccal root partially outside of the alveolar process.
6	9 mm	11 mm	2 mm	-
7	10 mm	10 mm	0 mm	-
8	9 mm	9 mm	0 mm	-
9	9 mm	9 mm	0 mm	-
10	9 mm	9 mm	0 mm	-
Mean ± SD	10.5 ± 2.84 mm	9.7 ± 2.05 mm	-0.8 mm	-

DB = distovestibular; T0 = before surgery (baseline); T1 = immediately before implant placement surgery.

**Table 3 Alveolar Vertical Height Changes Between T0 and T1**

Patient no.	Mesial (total)	Distal (total)	Vestibular	Palatal/lingual
1	1.8 mm	4.1 mm	1.3 mm	3.8 mm
2	-0.1 mm	2.8 mm	4.1 mm	-1.1 mm
3	-0.7 mm	-1.0 mm	2.5 mm	-1.7 mm
4	-0.2 mm	1.5 mm	5.7 mm	0.4 mm
5	-0.5 mm	-0.7 mm	3.9 mm	-0.2 mm
6	0.5 mm	4.8 mm	4 mm	1.4 mm
7	-0.3 mm	5.0 mm	-1 mm	0.2 mm
8	2.2 mm	2.3 mm	4.5 mm	0.1 mm
9	-0.2 mm	5.9 mm	0 mm	0.5 mm
10	-0.6 mm	3.2 mm	2.5 mm	2.2 mm
Mean change	0.2 mm	2.8 mm	2.8 mm	0.6 mm

T0 = before surgery (baseline); T1 = immediately before implant placement surgery. Values were calculated according to the methods explained in the Clinical Procedure section of the article.

d-PTFE membranes in the treatment of severely resorbed sockets (single-rooted teeth) and reported needing an additional augmentation in 47% of the cases.<sup>3</sup> In the present study, only one (11%) of the nine patients who

received an implant required an additional augmentation to correct an apical undercut of the alveolar process that was present preextraction. The difference between the study by Antonious et al and the present

study may be due to a more stable scaffold resulting from the use of the Ti-d-PTFE membrane in the present study.<sup>13</sup>

Although the present technique uses an open-healing environment, a



thin and reddish soft tissue was seen covering the graft under the membrane without any signs of infection. This clinical finding agreed with a previous clinical and histologic study.<sup>12</sup> Even though the membrane edge became exposed in 4 patients, creating a possibility for infection, no clinical signs of infection were observed at or after membrane removal in any of the 10 patients. In a histologic study on the healing of human sockets after extraction, Trombelli et al reported that a barrier function is no longer needed after 4 to 6 weeks due to the composition of the osteoid matrix.<sup>19</sup> Thus, in the present study, it was hypothesized that the osteoid matrix would maintain its dimensions at membrane removal, 4 to 6 weeks after extraction.

A positive side effect of the present technique is an increase in the amount of keratinized tissue, so no distortion of the mucogingival line occurs. The keratinized tissue width was increased to  $6.0 \pm 1.0$  mm, which corresponds with Barboza et al's findings.<sup>20</sup> The time between tooth extraction and implant placement was planned to be 5 to 6 months, but due to various reasons (insurance, patient relocation, etc), this was extended in four cases at the patients' requests.

Limitations of the present case series study included the small number of participants and exclusive treatment of posterior teeth. Future research should also focus on the anterior dentition with a thinner phenotype to investigate the feasibility of this technique. In addition, the present study did not include histologic analysis, but it has been well

studied in the past.<sup>10–12,21</sup> To the best of the present authors' knowledge, this is the first case series study on ridge preservation/restoration with Ti-d-PTFE membranes of severely resorbed extraction sockets. Thus, more research on this topic is needed, as well as additional research to compare the clinical performance with other membranes, such as collagen or nonreinforced d-PTFE.

## Conclusions

The ridge preservation/restoration technique used in this case series study showed good preservation and restoration of severely resorbed sockets after extraction and improved amounts of keratinized tissue. Thus, this technique allows easier implant placement with little need for additional augmentation. If implant therapy is indicated after tooth extraction and severely resorbed sockets are present, the use of a Ti-d-PTFE membrane is a realistic option.

## Acknowledgments

Dr Vroom and Dr Urban received honoraria for lecturing from Osteogenics Biomedical. The authors report no conflicts of interest related to this study.

## References

1. Van der Weijden F, Dell'Acqua F, Slot DE. Alveolar bone dimensional changes of post-extraction sockets in humans: A systematic review. *J Clin Periodontol* 2009;36:1048–1058.

2. Ten Heggeler JM, Slot DE, Van der Weijden GA. Effect of socket preservation therapies following tooth extraction in non-molar regions in humans: A systematic review. *Clin Oral Implants Res* 2011;22:779–788.
3. Antonious M, Couso-Queiruga E, Barwacz C, González-Martín O, Avila-Ortiz G. Evaluation of a minimally invasive alveolar ridge reconstruction approach in postextraction dehiscence defects: A case series. *Int J Periodontics Restorative Dent* 2021;41:335–345.
4. Grassi A, Bernardello F, Cavani F, Palumbo C, Spinato S. Three-punch alveolar ridge reconstruction technique: A novel flapless approach in eight consecutive cases. *Int J Periodontics Restorative Dent* 2021;41:875–884.
5. Scheyer ET, Heard R, Janakievski J, et al. A randomized, controlled, multicentre clinical trial of post-extraction alveolar ridge preservation. *J Clin Periodontol* 2016;43:1188–1199.
6. Tan-Chu JH, Tuminelli FJ, Kurtz KS, Tarnow DP. Analysis of buccolingual dimensional changes of the extraction socket using the "ice cream cone" flapless grafting technique. *Int J Periodontics Restorative Dent* 2014;34:399–403.
7. Sisti A, Canullo L, Mottola MP, Covani U, Barone A, Botticelli D. Clinical evaluation of a ridge augmentation procedure for the severely resorbed alveolar socket: Multicenter randomized controlled trial, preliminary results. *Clin Oral Implants Res* 2012;23:526–535.
8. Aimetti M, Manavella V, Corano L, Ercoli E, Bignardi C, Romano F. Three-dimensional analysis of bone remodeling following ridge augmentation of compromised extraction sockets in periodontitis patients: A randomized controlled study. *Clin Oral Implants Res* 2018;29:202–214.
9. Bartee BK. Extraction site reconstruction for alveolar ridge preservation. Part 1: Rationale and materials selection. *J Oral Implantol* 2001;27:187–193.
10. Hoffmann O, Bartee BK, Beaumont C, Kasaj A, Deli G, Zafiroopoulos GG. Alveolar bone preservation in extraction sockets using non-resorbable d-PTFE membranes: A retrospective non-randomized study. *J Periodontol* 2008;79:1355–1369.
11. Borg TD, Mealey BL. Histologic healing following tooth extraction with ridge preservation using mineralized versus combined mineralized-demineralized freeze-dried bone allograft: A randomized controlled clinical trial. *J Periodontol* 2015;86:348–355.

12. Laurito D, Cugnetto R, Lollobrigida M, et al. Socket preservation with d-PTFE membrane: Histological analysis of the newly formed matrix at membrane removal. *Int J Periodontics Restorative Dent* 2016;36:876–883.
13. Schenk RK, Buser D, Hardwick WR, Dahlin C. Healing pattern of bone regeneration in membrane-protected defects: A histologic study in the canine mandible. *Int J Oral Maxillofacial Implants* 1994;1:13–29.
14. Llewelyn MJ, Fitzpatrick JM, Darwin E, et al. The antibiotic course has had its day. *BMJ* 2017;358:j3418.
15. Mariotti AJ, Rumpf DA. Chlorhexidine-induced changes to human gingival fibroblast collagen and non-collagen protein production. *J Periodontol* 1999;70:1443–1448.
16. Araújo MG, Silva CO, Misawa M, Sukekava F. Alveolar socket healing: What can we learn? *Periodontology* 2000 2015;68:122–134.
17. Pietrokovski J, Massler M. Alveolar ridge resorption following tooth extraction. *J Prosthet Dent* 1967;17:21–27.
18. Monje A, Chappuis V, Monje F, et al. The critical peri-implant buccal bone wall thickness revisited: An experimental study in the beagle dog. *Int J Oral Maxillofac Implants* 2019;34:1328–1336.
19. Trombelli L, Farina R, Marzola A, Bozzi L, Liljenberg B, Lindhe J. Modeling and remodeling of human extraction sockets. *J Clin Periodontol* 2008;35:630–639.
20. Barboza EP, Stutz B, Mandarino D, Rodrigues DM, Ferreira VF. Evaluation of a dense polytetrafluoroethylene membrane to increase keratinized tissue: A randomized controlled clinical trial. *Implant Dent* 2014;23:289–294.
21. Fotek PD, Neiva RF, Wang HL. Comparison of dermal matrix and polytetrafluoroethylene membrane for socket bone augmentation: A clinical and histologic study. *J Periodontol* 2009;80:776–785.